Acta Zoologica

Published for The Royal Swedish Academy of Sciences and The Royal Danish Academy of Sciences and Letters

Acta Zoologica (Stockholm) doi: 10.1111/j.1463-6395.2012.00569.x

Characterization of mature testis and sperm morphology of *Gymnotus carapo* (Gymnotidae, Teleostei) from the southeast of Brazil

Cristiane dos S. Vergílio,[1] Renata V. Moreira,[1] Carlos E.V. de Carvalho[2] and Edésio J.T. de Melo[1]

[1]Laboratório de Biologia Celular e Tecidual, Centro de Biociências e Biotecnologia, Universidade Estadual do Norte Fluminense, Campos dos Goytacazes, RJ, 28013-602, Brazil; [2]Laboratório de Ciências Ambientais, Centro de Biociências e Biotecnologia, Universidade Estadual do Norte Fluminense, Campos dos Goytacazes, RJ, 28013-602, Brazil

Keywords:
Banded knifefish, gymnotidae, spermatogenesis, spermatozoa, testis structure

Accepted for publication:
23 April 2012

Abstract

Vergilio, C.S., Moreira, R.V., Carvalho, C.E.V. and Melo, E.J.T. 2012. Characterization of mature testis and sperm morphology of *Gymnotus carapo* (Gymnotidae, Teleostei) from the southeast of Brazil. —*Acta Zoologica* (Stockholm) **00**: 1–7.

The present study examined the testicular structure and sperm morphology of freshwater fish *Gymnotus carapo*. Testicular structure and sperm morphology were analyzed using light, transmission and scanning electron microscopy. Anatomically, the testes weighed 0.070 ± 0.01 g and were oval with a yellow-white color. The *G. caparo* testis is organized in interstitial and tubular compartments. Spermatogenesis occurs in seminiferous tubules where the germinal epithelium is organized in spermatogenic cystis. Germ cells are seen in different stages of differentiation: type A (SPGA) and type B (SPGB) spermatogonia, primary (SPCI) and secondary (SPCII) spermatocytes, and spermatids (SPD). Differentiated spermatozoa (SZ) are seen within the cysts, characterized by a round head, a short midpiece, and a single flagellum with absence of acrosome. Spermatids were seen in the lumen of the testicular tubules together with spermatozoa, suggesting that spermatogenesis is of the semicystic type. The present study shows that *G. carapo* has an anastomosing tubular type of testis with an unrestricted distribution of the spermatogonia and semicystic type of spermatogenesis. Sperm structure follows the general pattern described for other teleostei species. These descriptions are important for a better understanding of reproductive biology and phylogeny, particularly of tropical fishes, for which data remain scarce in the literature.

Edesio J. T. Melo. Laboratório de Biologia Celular e Tecidual, Centro de Biociências e Biotecnologia, Universidade Estadual do Norte Fluminense, Av. Alberto Lamego 2000, Parque Califórnia, CEP 28013-602, Campos dos Goytacazes, RJ, Brasil. E-mails: ejtm1202@gmail.com or ejtm@uenf.br

Introduction

Characterization of mature testis and sperm morphology of fish species might not only be important in systematics and phylogeny, but also have practical applications related to artificial fertilization and sperm preservation (Furbock *et al.* 2010). Owing to the large diversity of the fish fauna, data on spermatogenic ultrastructure in teleosts are scarce and restricted to a few species (Magalhães *et al.* 2011).

Gymnotus carapo (banded knifefish) is a tropical freshwater fish, belonging to the family Gymnotidae, widely distributed in South and Central America (Albert *et al.* 2004; Lovejoy *et al.* 2010). *Gymnotus carapo* are nocturnal predators of fishes and other small aquatic animals, and most are territorial (Crampton 1998). This species is largely used in professional and sportive fishery, as live bait it is preferred by higher predator fish species. Therefore, information about its reproductive biology is important for aquaculture programs.

© 2012 The Authors
Acta Zoologica © 2012 The Royal Swedish Academy of Sciences

Although aspects of reproductive dynamics and gonadal histology of *Gymnotus* sp. has already been described in the literature (Barbieri and Barbieri 1984; Cognato and Fialho 2006; França *et al.* 2007), a detailed characterization of testis structure and sperm morphology is still needed. Therefore, the present study examined the testicular structure and sperm morphology of the freshwater fish *Gymnotus carapo*.

Materials and Methods

Fish samples

Gymnotus carapo specimens (n = 36) used in the present study were all males in same sexual maturity stage, obtained from Cima Lake, northern part of Rio de Janeiro state (21° 46′ S and 41° 31′ W). The samples were collected from October 2009 to January 2010. This sampling season was during the peak of spermatogenic activity of *G. carapo* (Barbieri and Barbieri 1984; Cognato and Fialho 2006). These animals were measured, weighed, and dissected to take testis samples that were subsequently used for the morphological studies. The gonadosomatic index was determined using the following formula (De Vlaming *et al.* 1982): GSI = (gonadal weight/total body weight) ×100.

Analysis of testis morphology

Samples of testis of sexually mature males were fixed by immersion technique in 10% neutrally buffered formalin for 24 h, dehydrated in alcohol, cleared in xylene and embedded in paraffin. Sections (5 μm) were obtained using Leica RM 2125RT microtome and stained with hematoxylin and eosin (H&E) for examination by light microscopy. Digital images were obtained using an Axioplan microscope equipped with a Cannon PowerShot camera A610/620.

Small fragments of testis were also fixed by immersion technique for 24 h in 4% formaldehyde, 2.5% glutaraldehyde, 5% sucrose in 0.1 M cacodylate buffer, pH 7.2. The material was then post-fixed in (1 : 1) 1% osmium tetroxide and 0.8% potassium ferricyanide, dehydrated with acetone, and embedded in Epon®. Semithin (0.4 μm) and ultrathin (70 nm) sections were obtained with a Reichercuts Leica ultramicrotome. Semithin sections were stained with toluidine blue (1%) and examined by light microscope described previously. Ultrathin sections were contrasted with uranyl acetate and lead citrate for a Zeiss TEM 900 transmission electron microscope.

Sperm morphology

Testes (n = 4) were minced with anatomic scissors in 2 mL of 0.1 M cacodylate buffer (pH 7.2) for 5 min at room temperature. Seminal fluid was fixed in fixative solution (4% formaldehyde, 2.5% glutaraldehyde, 5% sucrose in 0.1 M cacodylate buffer, pH 7.2), attached onto a coverslip with poly-L-lysine, post-fixed in 1% osmium tetroxide, dehydrated in ethanol, critical-point dried in CO_2 (BAL-TEC CPD 030 Critical Point Dryer), and sputtered with gold (BAL-TEC SCD 050 Sputter Coater) for observation in a Zeiss Evo 40 microscope scanning electron at 15 kV, employing secondary electrons.

Results

Gymnotus carapo testes are paired, consistent, and oval organs with a yellow-white color (Fig. 1A,B) and weighted 0.070 ± 0.01 g (n = 36). They are located in the caudal extremity of viscera (Fig. 1A) during all maturation stages. The testis is connected by spermatic ducts to the cranial region, ending in the genital papilla (Fig. 1A), under the head immediately posterior to the anus. The mean gonadosomatic index (GSI) was 0.070 ± 0.002%.

Male gonads are surrounded by tunica albuginea (Fig. 2A), which is composed of connective fibers that enter the organ interior where it forms the interstitial tissue that subdivide the testis in irregular seminiferous tubules (Fig. 2B, *inset*; Fig. 3A–C). In the interstitial compartment (it, Fig. 2B–E; Fig. 3B), blood cells (Fig. 2D, *arrowhead*), neural connections, conjunctive tissue fibers, and Leydig cells are

Fig. 1—General aspect of *Gymnotus carapo* testis (**A**) Testicular localization in relation to other organs (**B**) shows the paired testis with ovoid aspect. Scale bars: 1 cm.

© 2012 The Authors
Acta Zoologica © 2012 The Royal Swedish Academy of Sciences

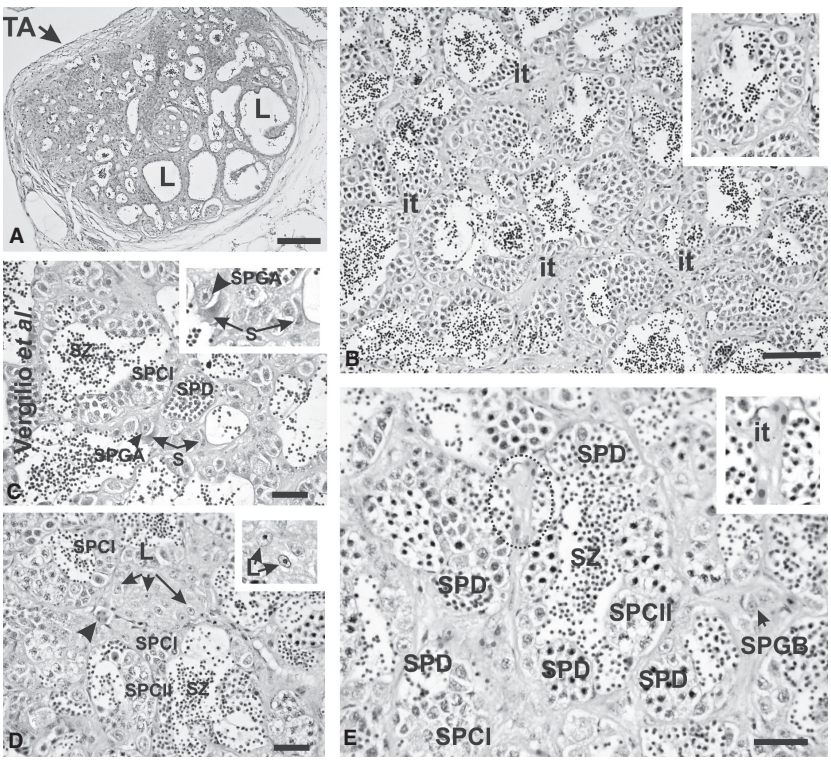

Fig. 2—Light microscopy of hematoxylin and eosin (**H&E**) stained *Gymnotus carapo* testis (**A**) Cross-section of testes surrounded by tunica albuginea (TA) (*arrow*) and lumen lobes (L) are also seen. —(**B**) Testicular organization with seminiferous lobes (*inset*) and interstitial tissue (it). —(**C**) Seminiferous lobes containing germ cells: primary spermatogonia (SGA), primary spermatocytes (SCI) and spermatids (SD). Spermatozoids (SZ) are also seen within the lobes lumen. Sertoli cells (S) are also present, supporting germ cells (*inset*). —(**D**) Interstitial tissue containing Leydig cells (L) (*inset*) also occurs between lobes and blood vessels (*arrowhead*). —(**E**) shows the arrangement of lobes surrounded by interstitial tissue (it) (*inset*). Scale bars: A: 200μm, B: 50μm (200×), **C–E**: 20μm (400×).

present. Leydig cells are large ovoid cells and usually appear in groups (Fig. 2D).

These cysts are lined by germinal epithelium containing germ cells (Fig. 2C–E, Fig. 3A,B) surrounded by Sertoli cells (Fig. 2C–E). Germ cells undergo different stages of differentiation as: type A (SPGA) and type B (SPGB) spermatogonia, spermatocytes (SPC), and spermatids (SPD) (Fig. 2C–E, Fig. 3A,B). In this cystic arrangement, the germ cells develop synchronously until sperm formation. Mature spermatozoa (SZ) can be found in the lumen of cysts (Fig. 2D,E).

For internal structure, the *G. carapo* testis has lobular type, in which the seminiferous tubules are grouped in many cysts, where spermatogenesis occurs. The tubules are anastomosing at different areas and mostly in the region of the spermatic duct. The lobular testis may also be divided into restricted and unrestricted types according to the distribution of spermatogonia (Parenti and Grier 2004). In *G. carapo* testis, the spermatogonia are unrestricted, being dispersed along the length of the lobule.

Type A spermatogonia (SPGA) are the largest cells of germ line, located in the base of germ epithelium, usually associated with Sertoli cells (Fig. 2C). SPGA have hyaline cytoplasm, a prominent nucleus, and one well-developed nucleolus that is centrally located (Fig. 2C, *inset*). Type B spermatogonia (SPGB) are characterized by a decrease in cell size compared to SPGA (Figs 3A, 2E), and differences in chromatin aggregation are also evident.

Spermatogonia divisions lead to spermatocyte formation. Spermatocytes are usually observed in different stages of the first meiotic division, being characterized as primary (SPCI) and secondary (SPCII) spermatocytes (Fig. 2C–E, Fig. 3A, B). These cells can present different degrees of nuclear material compaction (Fig. 2C–E, Fig. 3A,B). Spermatids (SPD) result from the second meiotic division and have a heterogeneous population in appearance (Fig. 2C–E, Fig. 3A,B; Fig. 4A). Owing to the spermatogenic process, there is size reduction as the nuclei become smaller, when the chromatin condenses (Fig. 4A,B). These cells were seen in the cyst (Fig. 2C–E, Fig. 3A,B) and also in the lumen (L) (Fig. 4A, B) next to the cyst periphery, in different stages of spermiation, and are recognizable by their large, darkly stained nucleus (Fig. 4A,B).

The presence of spermatids in the lumen of the testicular tubules together with spermatozoa suggests that spermatogenesis is of the semicystic type. Therefore, these cells are being released from the cysts for completion of the spermatogenic

© 2012 The Authors
Acta Zoologica © 2012 The Royal Swedish Academy of Sciences

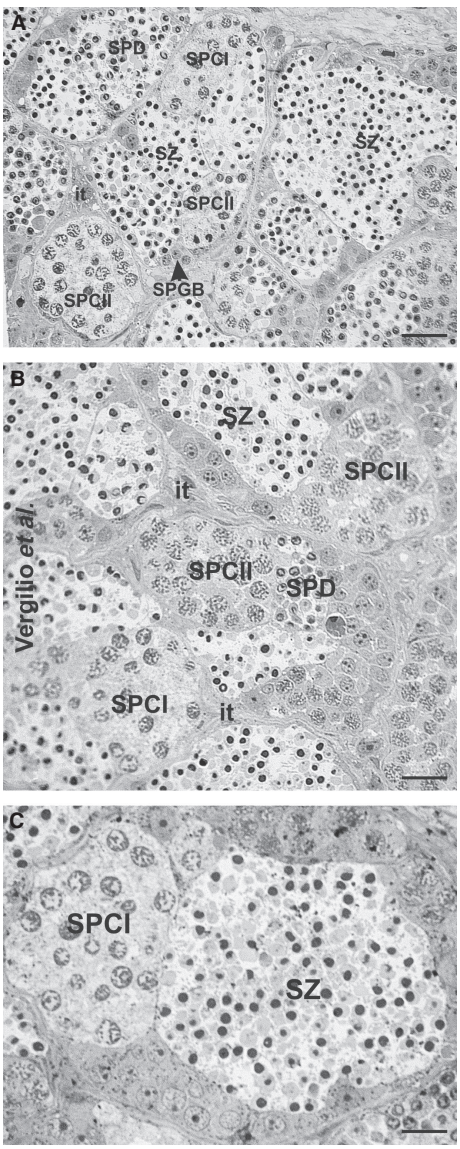

Fig. 3—Light microscopy of semithin sections of *Gymnotus carapo* testis stained with toluidine blue (**A**) shows organization of cysts connected by interstitial tissue (it) with germ cells in different stages of differentiation: Secondary spermatogonia (SGB), primary spermatocytes (SCI), secondary spermatocytes (SPCII) and spermatids (SD). Spermatozoa (SZ) are also seen within the lobes lumen. (**B**) and (**C**) also shows details of cyst arrangement. Scale bars: A–B: 20 μm (200×), C: 20 μm (400×).

process in the lumen of the seminiferous lobules. Subsequently, spermatozoa (SZ) are characterized by extraordinary nuclear compaction and cytoplasmatic reduction (Fig. 2C–E, Fig. 3A–C, Fig. 4C–F, Fig. 5).

The *G. carapo*-differentiated spermatozoa are characterized by a head, a short midpiece, single flagellum, and absence of acrosome (Fig. 4C–F, Fig. 5). The head measured about 2.3 μm in diameter and was occupied almost totally by the nucleus (Fig. 4B–F). It has an ovoid shape (Fig. 5) and contains highly electron dense chromatin, homogeneously dispersed (Fig. 4C–F). At the base of the nucleus, the nuclear envelope invaginated, forming a depression called the nuclear fossa (Fig. 4E,F *arrows*).

The midpiece is short, with ovoid mitochondria and some vesicles clustered in regions close to the plasma membrane (Fig. 4C). Inserted in the midpiece, close to the nucleus is also the centriolar complex, which is formed by proximal and distal centrioles (Fig. 4C). The flagellum is lateral and parallel to the nucleus, measuring about 26 μm in length, and has the classical 9 + 2 microtubular pattern (Fig. 4D, *inset*). It has a cylindrical shape through its length, and the flagellar membrane does not have lateral projections (Fig. 4C–E, Fig. 5).

Discussion

The determination of mature reproductive stage based in germ cells and alterations of germinal epithelium is an important tool for characterization of reproductive biology in teleosts (Grier 1981). As *G. carapo* males do not show alterations in testis external morphology, accurate identification of distinct maturation stage, knowledge of the reproductive cycle, and microscopic analysis are necessary.

In the present study, the male fish were in a mature stage as indicated by advanced spermatogenic process. According to Barbieri and Barbieri (1984), the *G. carapo* spermatogenic activity occurs throughout the year but with intensity changes, being higher from November to January and reaching a peak between October and December. *Gymnotus carapo* spring–summer reproductive cycle was also observed by Cognato and Fialho (2006) as occurring between November and March.

The testis size and GSI of mature *G. carapo* were very small throughout spermatogenic development. This feature, also observed in *Solea senegalensis* (García-López *et al.* 2005), is rare in other teleosts, which shows higher percentage of testis relative to overall body.

The ovoid external morphology of the *G. carapo* testis with two long spermatic ducts differs from the description of an elongated testis extensive through all abdominal cavity of most teleost fishes (Barbieri and Barbieri 1984). Testis organization in two compartments, the interstitial and tubular compartments, is observed in all vertebrates, from fish to mammals (Schulz *et al.* 2010). The interstitial compartment is composed of Leydig cells, blood/lymphatic vessels, macrophages and mast cells, neural and connective tissue cells (Koulish *et al.* 2002) and is continuous with the tunica albuginea, composed of fibrous tissue that surrounds the organ (Rupik *et al.* 2011).

Seminiferous tubules contain spermatogenic cysts formed by Sertoli cells that sustain synchronously developing germ cells. This cystic spermatogenesis occurs in fish and amphibians (Santos and Oliveira 2008). The morphology of different germ cell types observed for *G. carapo* is similar to those

© 2012 The Authors
Acta Zoologica © 2012 The Royal Swedish Academy of Sciences

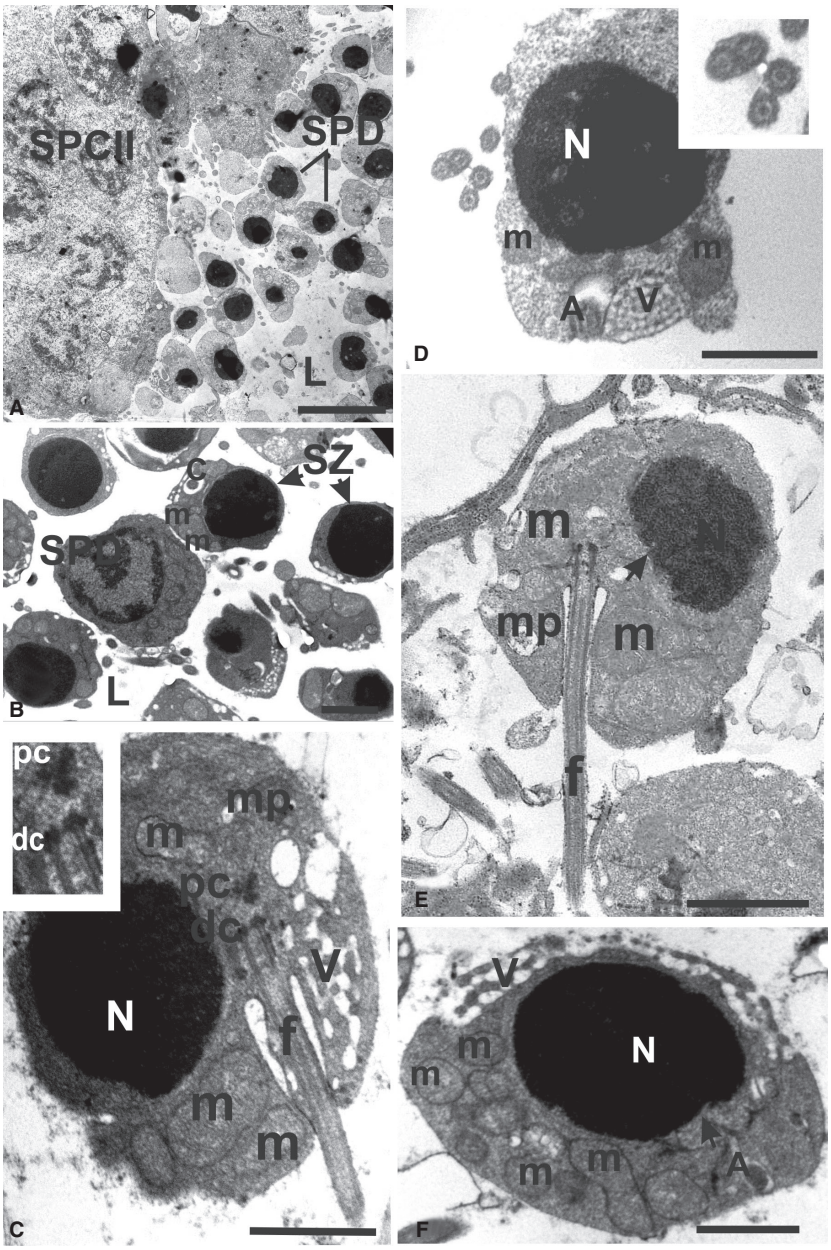

Fig. 4—Transmission electron microscopy of *Gymnotus carapo* testis. —(**A**) shows a cyst with secondary spermatocytes (SPCII) and spermatids (SPD) released in the cyst lumen (L). The presence of spermatids (SPD) together with spermatozoa (SZ) is demonstrated in (**B**). —(**C**) shows details of spermatozoa structure as the short midpiece (mp), ovoid mitochondria (m), the lateral and parallel position of the flagellum (f), the centriolar complex which is formed by proximal (pc) and distal centrioles (pd) and some vesicles (V) clustered in regions close to the plasma membrane. —(**D**) shows the axoneme (**A**) of flagellum with the classical 9 + 2 microtubular pattern (*inset*). —(**E**) shows the nuclear fossa (*arrows*) at the base of the nucleus as an invagination of the nuclear envelope forming a depression. In (**F**) is demonstrated nucleus with highly electron dense chromatin, homogeneously dispersed. N= nucleus, A= axoneme. Scale bars: A and E: 1 μm, B–D and F: 500 nm.

described for most species of teleost fish (Leal *et al.* 2009; Muñoz *et al.* 2011; Rupik *et al.* 2011).

For *G. carapo*, the presence of both spermatids and spermatozoa in the lumen of the testicular lobules suggests that spermatogenesis is of the semicystic type. Semicystic spermatogenesis is also found in different taxonomic groups, such as Characidae (*Hemigrammus marginatus*) (Magalhães *et al.* 2011), Scorpaenidae (*Scorpaena notata*) (Muñoz *et al.* 2002; Sàbat *et al.* 2009), Opheliidae (Mattei 1993; Hernández *et al.* 2005), Siluriformes (*Malapterurus electricus*) (Shahin 2006), Soleidae (*Solea senegalensis*) (García-López *et al.* 2005), Corydoradinae *(Corydoras flaveolus, Corydoras aeneus, Sclero-*

© 2012 The Authors
Acta Zoologica © 2012 The Royal Swedish Academy of Sciences

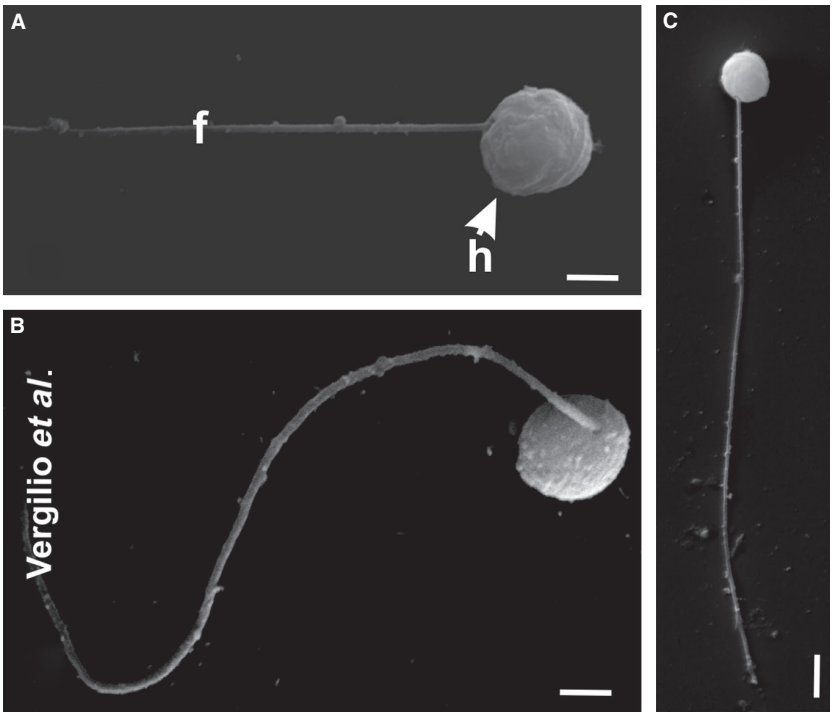

Fig. 5—Morphology of *Gymnotus carapo* spermatozoa. —(**A–C**) show scanning electron microscopy of sperm. Round head (H) and flagellum (F) can be seen. Scale bars: 1μm.

mystax lacerdai, *Aspidoras poecilus*) (Spadella *et al.* 2007), and Bleniidae (Lahnsteiner and Patzner 1990). The fact that individual spermatids from different germ cell clones proceed through spermiogenesis in the tubular lumen seems but a variation of the timing of germ cell individualization (Schulz *et al.* 2010).

The patterns of spermatozoa structure are highly conserved within taxonomic groups, thus being a powerful tool for phylogenetic analyses in fish (Jamieson 1991). Fish spermatozoa can be classified according to the external or internal mode of fertilization into two forms, aquasperm and introsperm, respectively (Jamieson 1991). *Gymnotus carapo* spermatozoa show the typical organization of externally fertilizing teleosts (Matos *et al.* 1998; Mansour *et al.* 2002; Furbock *et al.* 2010), as they have an ovoid nucleus, a small midpiece, and no acrosome. This differs from sperm of internally fertilizing fishes, which have an elongated head and a more complicated midpiece structure (Lahnsteiner *et al.* 1997).

Based on flagellum orientation and the occurrence of nuclear rotation, three types of spermiogenesis (type I, II, and III) have been described (Mattei 1970, Jamieson 1991; Schulz *et al.* 2010). In *G. caparo*, type II spermatogenesis occurs as the flagellum develops parallel to the nucleus without nuclear rotation. This type of spermatogenesis is characteristic of more derived teleosts like Perciformes, but also occurs in Characiformes (Silveira *et al.* 2006). The type II aquasperm has also been described for other gymnotiform species (França *et al.* 2007).

Conclusion

The present study shows that *G. carapo* testis and sperm structure follow the general pattern described for other teleost species. These descriptions are very important for a better understanding of reproductive biology, particularly of tropical fishes, for which data remain scarce in the literature. Moreover, it can also be helpful for this species' aquaculture programs.

Acknowledgements

This work was supported by Fundação Carlos Chagas Filho de Amparo à Pesquisa do Estado do Rio de Janeiro (E-26/171.315/2004) (E-26/100.470/2007) (E-26/110.921/2008).

References

Albert, J. S., Crampton, W. G. R., Thorsen, D. H. and Lovejoy, N. R. 2004. Phylogenetic systematics and historical biogeography of the Neotropical electric fish *Gymnotus* (Teleostei: Gymnotidae). – *Systematics and Biodiversity* **2:** 375–417.

Barbieri, C. B. and Barbieri, G. 1984. Reprodução de *Gymnotus carapo* (Linnaeus, 1758) na represa do Lobo (SP). Morfologia e histo-

© 2012 The Authors
Acta Zoologica © 2012 The Royal Swedish Academy of Sciences

logia de testículo. Variação sazonal. (Pisces, Gymnotidae). – *Revista Brasileira de Biologia* **44:** 141–148.

Cognato, D. P. and Fialho, C. B. 2006. Reproductive biology of a population of *Gymnotus* aff. *carapo* (Teleostei: Gymnotidae) from southern Brazil. – *Neotropical Ictiology* **4:** 339–348.

Crampton, W. G. R. 1998. Electric signal design and habitat preferences in a species rich assemblage of gymnotiform fishes from the upper Amazon Basin. – *Anais da Academia Brasileira de Ciência* **70:** 805–847.

De Vlaming, V. L., Grossman, G. and Chapman, F. 1982. On the use of gonadosomatic index. – *Comparative Biochemistry and Physiology* **73:** 31–39.

França, G. F., Oliveira, C. and Grassioto, I. Q. 2007. Ultrastructure of spermiogenesis and spermatozoa of *Gymnotus cf. anguillaris* and *Brachyhypopomus cf. pinnicaudatus* (Teleostei: Gymnotiformes). – *Tissue and Cell* **39:** 131–139.

Furbock, S., Patzner, R. A. and Lahnsteiner, F. 2010. Fine structure of spermatozoa of *Chondrostoma nasus* and *Rutilus meidingerii* (Teleostei, Cyprinidae), as revealed by scanning and transmission electron microscopy. – *Acta Zoologica* **91:** 88–95.

García-López, Á., Martínez-Rodríguez, G. and Sarasquete, C. 2005. Male reproductive system in Senegalese sole *Solea senegalensis* (Kaup): Anatomy, histology and histochemistry. – *Histology and Histopathology* **20:** 1179–1189.

Grier, H. J. 1981. Cellular organization of the testis and spermatogenesis in fishes. – *American Zoologist* **21:** 345–357.

Hernández, M. R., Sàbat, M., Muñoz, M. and Casadevall, M. 2005. Semicystic spermatogenesis and reproductive strategy in *Ophidion barbatum* (Pisces, Ophidiidae). – *Acta Zoologica (Stockholm)* **86:** 295–300.

Jamieson, B. G. M., 1991. Fish Evolution and Systematics: Evidence from Spermatozoa. Cambridge University Press, Cambridge.

Koulish, S., Kramer, C. R. and Grier, H. J. 2002. Organization of the male gonad in a protogynous fish, *Thalassoma bifasciatum* (Teleostei: Labridae). – *Journal of Morphology* **254:** 292–311.

Lahnsteiner, F. and Patzner, R. A. 1990. Spermiogenesis and structure of mature spermatozoa in bleniid fishes (Pisces, Bleniidae). – *Journal of Submicroscopic Cytology and Pathology* **22:** 565–576.

Lahnsteiner, F., Berger, B., Weismann, T. and Patzner, R. A. 1997. Sperm structure and motility of the freshwater teleost *Cottus gobio*. – *Journal of Fish Biology* **50:** 564–574.

Leal, M. C., Waal, P. P., López, A. G., Chen, S. X., Bogerd, J. and Schulz, R. W. 2009. Zebrafish primary testis tissue culture: An approach to study testis function *ex vivo*. – *General and Comparative Endocrinology* **162:** 134–138.

Lovejoy, N. R., Lester, K., Crampton, W. G. R., Marques, F. P. L. and Albert, J. S. 2010. Phylogeny, biogeography, and electric signal evolution of Neotropical knifefishes of the genus *Gymnotus* (Osteichthyes: Gymnotidae). – *Molecular Phylogenetics and Evolution* **54:** 278–290.

Magalhães, A. L. B., Andrade, R. F., Gomes, B. V. C., Perini, V. R., Rizzo, E. and Bazzoli, N. 2011. Ultrastructure of the semicystic spermatogenesis in the South American freshwater characid *Hemigrammus marginatus* (Teleostei, Characiformes). – *Journal of Applied Ichthyology* **27:** 1041–1046.

Mansour, N., Lahnsteiner, F. and Patzner, R. A. 2002. The spermatozoon of the African catfish: Fine structure, motility, viability and its behavior in seminal vesicle secretion. – *Journal of Fish Biology* **60:** 545–560.

Matos, E., Matos, P., Santos, M. N. S. and Azevedo, C. 1998. Aspectos morfológicos do espermatozóide de *Curimata inornata* Vari, 1989 (Pisces, Teleostei) do rio Amazonas. – *Acta Amazonica* **28:** 449–453.

Mattei, X. 1970. Spermiogenése comparé des poisson. In: Baccetti, B. (Ed.): *Comparative Spermatology*, pp. 57–72, Academic Press, New York.

Mattei, X. 1993. Peculiarities in the organization of testis of *Ophidion* sp. (Pisces: Teleostei). Evidence for two types of spermatogenesis in teleost fish. – *Journal of Fish Biology* **43:** 931–937.

Muñoz, M., Casadevall, M. and Bonet, S. 2002. Testicular structure and semicystic spermatogenesis in a specialized ovuliparous species: *Scorpaena notata* (Pisces, Scorpaenidae). – *Acta Zoologica* **83:** 213–219.

Muñoz, M. E., Batlounia, S. R., Vicentini, I. B. F. and Vicentini, C. A. 2011. Testicular structure and description of the seminal pathway in *Leporinus macrocephalus* (Anostomidae, Teleostei). – *Micron* **42:** 892–897.

Parenti, L. R. and Grier, H. J. 2004. Evolution and phylogeny of gonad morphology in bony fishes. – *Integrative and Comparative Biology* **44:** 333–348.

Rupik, W., Huszno, J. and Klag, J. 2011. Cellular organisation of the mature testes and stages of spermiogenesis in *Danio rerio* (Cyprinidae; Teleostei) – Structural and ultrastructural studies. – *Micron* **42:** 833–839.

Sàbat, M., Lo Nostro, F., Casadevall, M. and Munõz, M. 2009. A light and electron microscopic study on the organization of the testis and the semicystic spermatogenesis of the genus *Scorpaena* (Teleostei, Scorpaenidae). – *Journal of Morphology* **270:** 662–672.

Santos, L. R. S. and Oliveira, C. 2008. Histological aspects and structural characteristics of the testes of *Dendropsophus minutus* (Anura, Hylidae). – *Micron* **39:** 1266–1270.

Schulz, R. W., França, L. R., Lareyre, J. J., LeGac, F., Garcia, H. C., Nobrega, R. H. and Miura, T. 2010. Spermatogenesis in fish. – *General and Comparative Endocrinology* **165:** 390–411.

Shahin, A. A. B. 2006. Semicystic spermatogenesis and biflagellate spermatozoon ultrastructure in the Nile eletric catfish *Malapterurus electricus* (Teleostei: Siluriformes: Malapteruridae). – *Acta Zoologica* **87:** 215–227.

Spadella, M. A., Oliveira, C. and Quagio-Grassiotto, I. 2007. Comparative analyses of spermiogenesis and sperm ultrastructure in Callichthyidae (Teleostei: Ostariophysi: Siluriformes). – *Neotropical Ichthyology* **5:** 337–350.

© 2012 The Authors
Acta Zoologica © 2012 The Royal Swedish Academy of Sciences